

Tracheal Reconstruction Using Tissue-Engineered Cartilage

J. Fredrik Grimmer, MD; Chad B. Gunnlaugsson, MD; Eben Alsberg, PhD; Hedwig S. Murphy, MD, PhD; Hyun Joon Kong, PhD; David J. Mooney, PhD; Robert A. Weatherly, MD

Objectives: To determine whether rabbit cartilage can be tissue engineered using a polyglycolic acid (PGA) construct composed of PGA mesh, autologous chondrocytes, and alginate covalently linked with the cell adhesion sequence arginine-glycine-aspartic acid (RGD), and to investigate the feasibility of reconstructing tracheal defects using the PGA construct in conjunction with a bioabsorbable intratracheal stent.

Methods: Nineteen New Zealand White rabbits were used. Nine rabbits underwent subcutaneous implantation of 3 different PGA construct combinations: (1) PGA, autologous chondrocytes, and RGD-modified alginate; (2) PGA, autologous chondrocytes, and unmodified alginate; and (3) PGA and RGD-modified alginate. The remaining 10 animals underwent anterior tracheal reconstruction using fascia lata grafts and the complete PGA construct (PGA, autologous chondrocytes, and RGD-modified alginate). At the time of tracheal reconstruction, a poly-L-lactic acid intratracheal stent was placed in 5 of these latter animals. Rates of tracheal stenosis and mortality were compared with those of historical control animals. Histologic analysis was performed on the PGA constructs.

Results: In the subcutaneous implants, the PGA constructs made with chondrocytes (with and without RGD) demonstrated mature cartilage formation in 7 (78%) of the 9 animals. No cartilage was seen in PGA constructs made without chondrocytes. Two of the 10 animals that underwent tracheal reconstruction with the complete PGA construct survived to 20 weeks and demonstrated patent airways, 1 with a stent and 1 without a stent (80% overall mortality). Histologic analysis showed mature cartilage formation at the tracheal reconstruction site. Historical control animals that underwent reconstruction with fascia lata alone demonstrated the lowest overall mortality.

Conclusions: Cartilage can be tissue engineered in rabbits using PGA mesh embedded with alginate-encapsulated autologous chondrocytes. It is also possible to reconstruct tracheal defects with this method of cartilage engineering, although the mortality rate in this study is high.

Arch Otolaryngol Head Neck Surg. 2004;130:1191-1196

From the Departments of Otolaryngology (Drs Grimmer, Gunnlaugsson, and Weatherly) and Biomedical Engineering (Drs Alsberg, Kong, and Mooney), University of Michigan, Ann Arbor; and Department of Pathology and Laboratory Medicine, Veterans Affairs Ann Arbor Health System (Dr Murphy). Dr Grimmer is now with Children's Hospital Boston, Boston, Mass. Dr Weatherly is now with the Department of Otolaryngology, University of Kansas, Kansas City. The authors have no relevant financial interest in this article.

VARIOUS METHODS HAVE been used to repair long-segment tracheal stenosis, with unacceptable morbidity and mortality.¹⁻⁴ Tissue-engineered cartilage may offer a solution by providing a rigid graft, in abundant supply, with the potential for shaping it to a given defect and with a low probability of a significant host reaction. Vacanti et al⁵ and Sakata et al⁶ have developed tissue-engineered cartilage to replace small tracheal defects in mice and have grown tracheal epithelial cells over the engineered tissue. It is our hypothesis that a biodegradable construct composed of polyglycolic acid (PGA) mesh and seeded with alginate-encapsulated chondrocytes will facilitate in situ growth of viable cartilage. We propose that PGA mesh will provide a temporary semirigid scaffolding on

which cartilage formation can occur. Chondrocyte growth and cartilage matrix formation may be enhanced by covalently binding arginine-glycine-aspartic acid (RGD) to the backbone of the alginate molecule in a hydrogel suspension.⁷⁻⁹ Furthermore, use of a poly-L-lactic acid (PLLA) intratracheal stent^{10,11} may provide rigid support to a reconstructed tracheal segment until new cartilage growth occurs.

The 2 main objectives of the present study were (1) to investigate whether rabbit cartilage could be tissue engineered subcutaneously using a PGA construct composed of PGA mesh, autologous chondrocytes, and RGD-modified alginate and (2) to investigate the feasibility of reconstructing tracheal defects using the PGA construct in conjunction with a PLLA intratracheal stent in the same animal model.

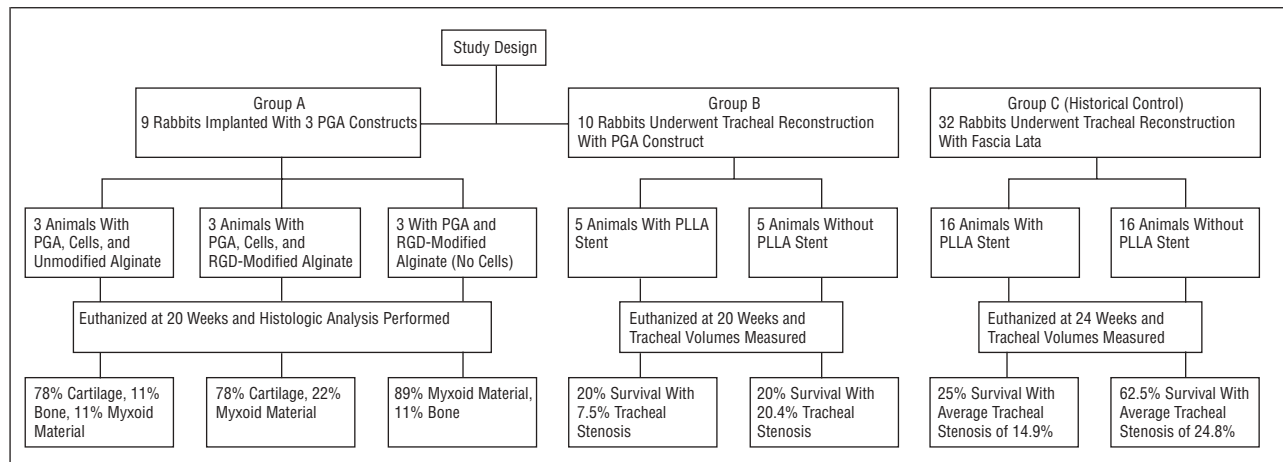


Figure 1. Study design. Group A: 9 animals total (3 subgroups) had 3 different polyglycolic acid (PGA) constructs implanted subcutaneously. The first construct consisted of PGA mesh embedded with chondrocytes suspended in unmodified alginate. The second consisted of PGA mesh with chondrocytes suspended in alginate crosslinked to the cell adhesion sequence arginine-glycine-aspartic acid (RGD) (an oligopeptide). The third consisted of PGA with RGD-modified alginate alone (no cells). Group B: 10 animals underwent tracheal reconstruction using PGA mesh embedded with chondrocytes suspended in RGD-modified alginate. Five of these animals also had a bioabsorbable poly-L-lactic acid (PLLA) tracheal stent placed at the time of their reconstruction. Group C: 32 animals (controls) underwent tracheal reconstruction with fascia lata alone; 16 of the 32 animals also had PLLA intratracheal stents placed at the time of reconstruction.

METHODS

STUDY DESIGN

Nineteen New Zealand white rabbits were used. Institutional guidelines regarding animal experimentation were followed. Nine rabbits at 11 to 13 weeks of age with an average weight of 2.3 kg (range, 2.2-2.7 kg) underwent subcutaneous implantation in their flanks with 3 different PGA construct combinations: (1) PGA, autologous chondrocytes, and RGD-modified alginate; (2) PGA, autologous chondrocytes, and unmodified alginate; and (3) PGA and RGD-modified alginate (group A, **Figure 1**). The remaining 10 rabbits were 8 to 10 weeks of age, weighed on average 1.5 kg (range, 1.4-1.7 kg), and underwent anterior tracheal reconstruction using the complete PGA construct (with autologous chondrocytes and RGD-modified alginate) and fascia lata (group B, **Figure 1**). Five of the group B animals also had a PLLA intratracheal stent placed at the time of reconstruction. Groups B animals were compared with 32 historical control animals that had undergone tracheal reconstruction with fascia lata alone at 10 to 12 weeks (average weight, 1.9 kg) for same-sized defects (group C, **Figure 1**). Half of the group C animals also had a PLLA intratracheal stent placed at the time of reconstruction.

CARTILAGE ISOLATION (GROUPS A AND B)

Animals in groups A and B underwent chondrocyte isolation from one of their own auricles. The rabbits were anesthetized with ketamine hydrochloride (35 mg/kg), xylazine chloride (5 mg/kg), and butorphanol (0.1 mg/kg) administered intramuscularly, and given one dose of intramuscular chloramphenicol (50 mg/kg) preoperatively. The left ear was prepared and draped in standard sterile fashion. The entire left pinna was removed near the attachment to the scalp. The wound was closed and the soft tissue and perichondrium was dissected off the harvested auricular cartilage. The cartilage was minced into 1- to 3-mm³ pieces and placed in a 50-mL conical vile containing Dulbecco modified Eagle medium (DMEM), 10% fetal bovine serum, and penicillin-streptomycin. The minced cartilage was then weighed and digested in fresh medium (DMEM, 10% fetal bovine serum, and penicillin-streptomycin) containing type II collagenase (1 mg/mL) at 37°C for 18 hours.^{12,13} After diges-

tion, the suspension was passed through a sterile 100-mm nylon mesh and then centrifuged. Cell numbers in resuspended medium were determined by Coulter counter method. Cell viability was determined by the trypan blue exclusion test using a hemocytometer. Isolated cells were then collected by repeat centrifugation in preparation for resuspension.

PGA CONSTRUCT PREPARATION (GROUPS A AND B)

Sterile liquid sodium alginate (ProNova Biopolymers, Drammen, Norway) covalently linked with RGD cell adhesion ligand (protein and structure core facilities at the University of Michigan) was prepared at a concentration of 2% (wt/vol) and dissolved in sterile tissue medium as previously described.¹⁴ Freshly isolated cells were added to the alginate yielding a cellular density of 1×10^6 cells/mL. The chondrocyte suspension was infused into precut sterile pieces of PGA mesh (average thickness of 1.5 mm). Each of the 3 rectangular subcutaneous implants measured 15 × 6 mm. The PGA constructs for tracheal reconstruction had an elliptical shape and measured 18 × 6.5 mm. Once each piece of PGA mesh had absorbed the suspension to its capacity, it was immersed in a sterile bath of calcium chloride (1M) to promote gel formation in the construct.

SUBCUTANEOUS IMPLANTATION (GROUP A)

On the day after cell harvest, the group A animals were again anesthetized as described above. Their flanks were shaved, prepared, and draped in standard sterile fashion. Three incisions were made in the flank. Pockets were developed between the superficial fascial plane and the deep back muscles. The previously prepared PGA constructs were sutured to the muscle fascia at the base of individually dissected pockets and the incisions were closed using running suture.

TRACHEAL RECONSTRUCTION (GROUPS B AND C)

On the day after cell harvest, the PGA constructs were prepared as described above. The group B animals were anesthetized as for the cartilage harvest. The anterior part of the neck was shaved, prepared, and draped in standard sterile fashion. The cervical trachea was exposed for a length of approxi-

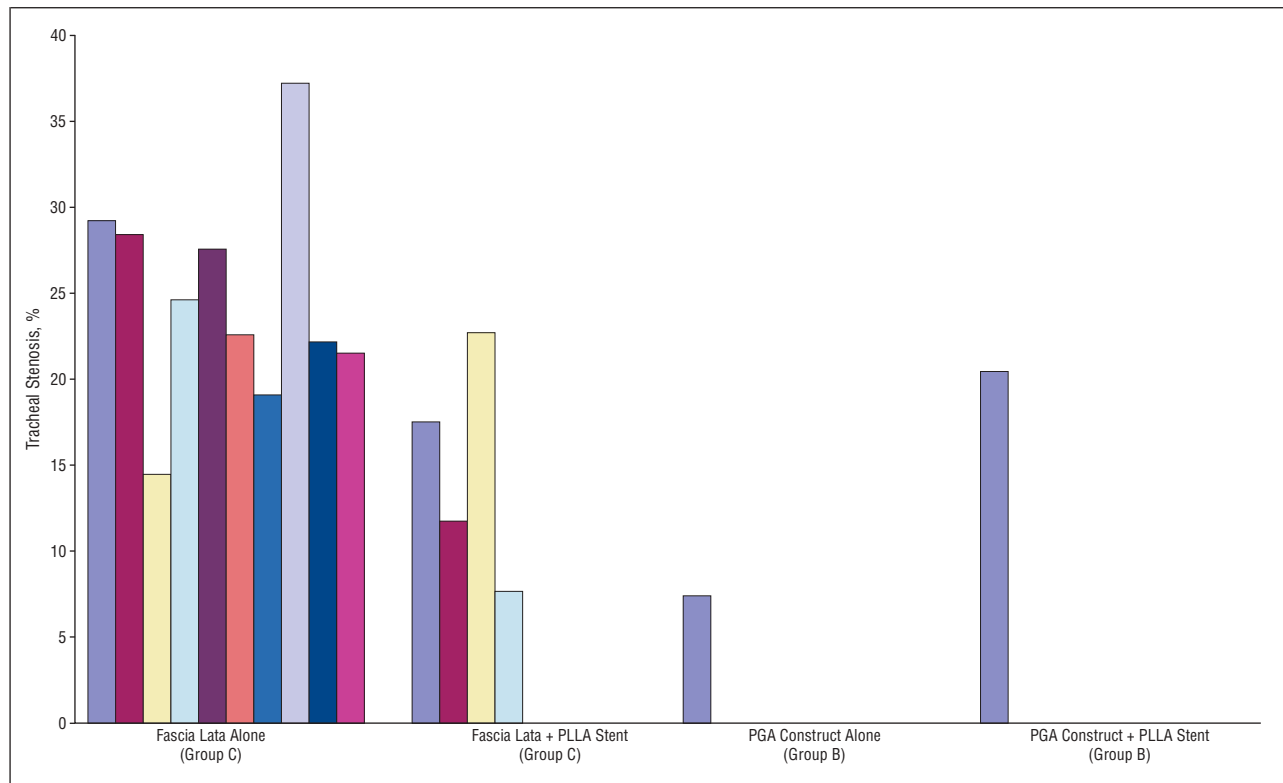


Figure 2. The surviving animal reconstructed with polyglycolic acid (PGA) construct alone (group B) had the least degree of stenosis (7.5%) of all animals. Animals in group C were humanely killed at 24 weeks; animals in group B were humanely killed at 20 weeks. PLLA indicates poly-L-lactic acid.

mately 3 cm. A vertical ellipse of the tracheal wall was excised after tracing the shape from a sterile template measuring 15×3.5 mm. In the appropriately designated animals (5 of the 10 group B rabbits), the PLLA “finger trap” stent (Bionx Implants, Blue Bell, Pa) with an outer diameter of 6 mm and length of 2 cm was introduced through the defect into the tracheal lumen. In all group B animals, the defect was then patched by suturing a slightly larger ellipse (18×6.5 mm) of glutaraldehyde-prepared homologous fascia lata¹² (stored in lactated Ringer solution) into place. The previously prepared PGA construct (18×6.5 mm) was then sewn over the fascia lata graft using 5-0 running polydioxanone suture. The wound was closed in the usual fashion.

Thirty-two historical control animals (group C) underwent anterior tracheal reconstruction with fascia lata alone as described by Robey et al.¹¹ Sixteen of the 32 animals also had PLLA stents placed intraluminally at the time of reconstruction (group C, Figure 1). The group B and C animals underwent bronchoscopy using a telescopic rod-camera system every 2 weeks. If there was any evidence of critical obstruction from mucus plugs, granulation tissue, or small stent fragments, these were removed if possible. Otherwise, the animals’ tracheas were allowed to heal unmolested.

ANALYSIS

Animals in groups A and B were euthanized at 20 weeks. Animals in group C were euthanized at 24 weeks. Larynges and PGA constructs were harvested at the time of euthanasia. Polyvinylsiloxane (PVS) impressions were obtained of the tracheal lumen. The casts were cut into 3-cm segments centered around the stenotic area. The proximal and distal ends of the PVS casts were measured to calculate the average surface area across the segment. Expected volume calculations were made based on

the average elliptical surface area of the ends multiplied by the length of the segment. The expected volume served as an approximation of the tracheal segment had there not been a stenosis. To determine the exact volume of the tracheal segment with stenosis, the volume of the PVS cast was measured using a water displacement method. The measured PVS cast volume was then used to calculate a percent stenosis relative to the expected (calculated) volume.

After the PVS casts were obtained, the tracheas and implants were fixed in 10% formalin, embedded in paraffin, and sectioned with a microtome. The slides were stained with hematoxylin-eosin and evaluated under light microscopy. An assessment was made of qualitative features examining for evidence of new cartilage growth and inflammatory changes.

RESULTS

Only 1 (20%) of the 5 animals reconstructed with the complete PGA construct and PLLA stent (group B, with stent) survived to 20 weeks. Ongoing bronchoscopy demonstrated an elliptical airway. Volume measurements demonstrated an estimated 20.4% stenosis (Figure 2). Three of the 4 other animals died of presumed airway obstruction. At necropsy and during bronchoscopy, the PLLA stents were found to fold inward at the proximal and distal ends. One of these 5 animals died of an anesthetic complication following bronchoscopy.

One (20%) of the 5 animals reconstructed with the complete PGA construct alone (group B, no stent) survived to 20 weeks and demonstrated a widely patent airway on bronchoscopy. Volume measurements demonstrated an estimated 7.5% stenosis, the smallest percent

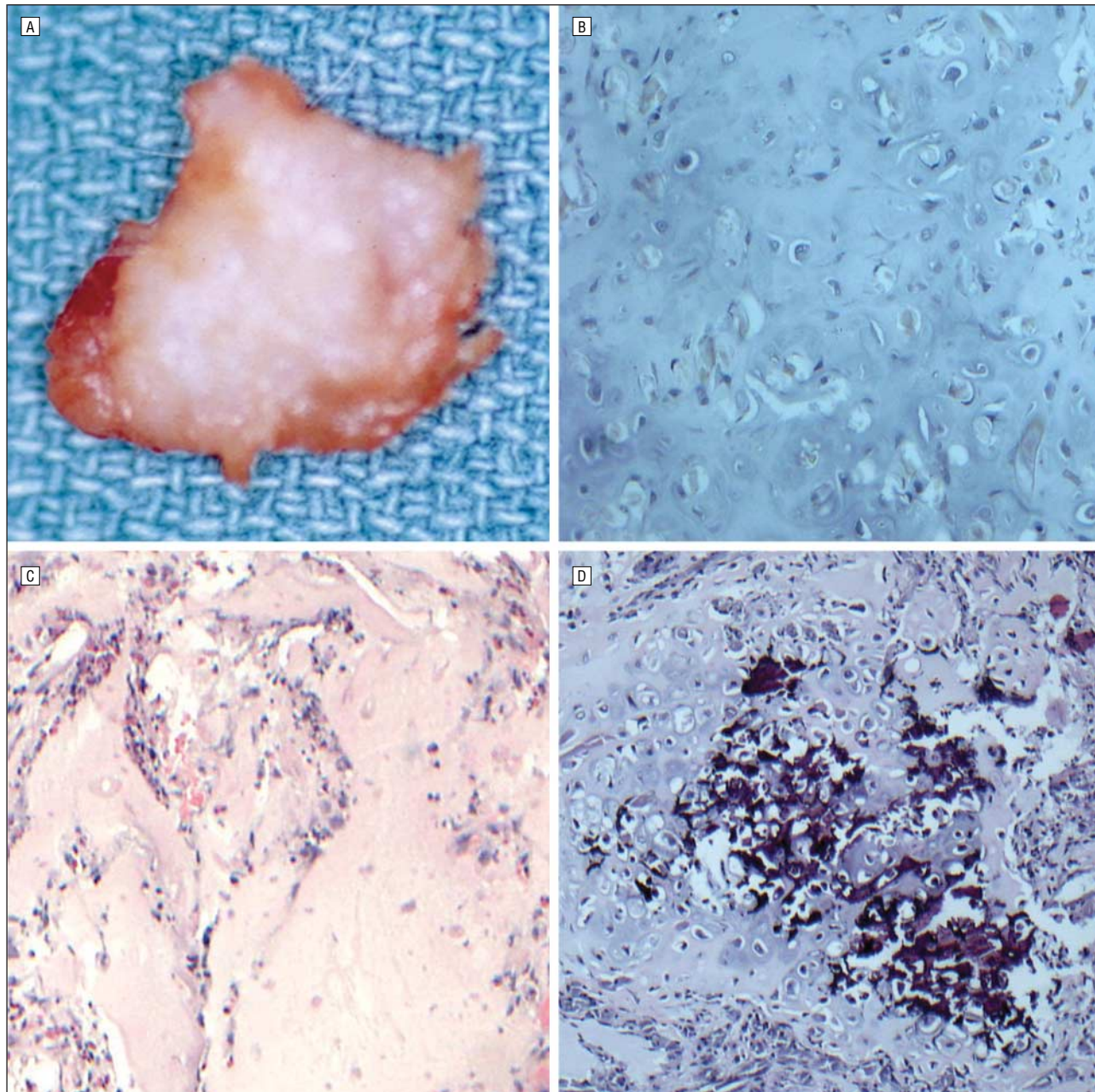


Figure 3. Animals were humanely killed at 20 weeks. Hematoxylin-eosin staining was performed on all polyglycolic acid (PGA) constructs in groups A and B. A, In the group A animals, PGA constructs made with chondrocytes (with and without the cell adhesion sequence arginine-glycine-aspartic acid [RGD]) showed cartilagelike appearance on gross examination. B, Histologic analysis confirmed cartilage formation. C, PGA constructs made without chondrocytes demonstrated myxoid material on histologic examination. D, The only surviving stented group B animal demonstrated cartilage formation at the tracheal reconstruction site.

stenosis of any of the animals in our study (Figure 2). The other 4 animals in this group died of presumed airway obstruction based on bronchoscopic examination and necropsy results.

Ten of the 16 animals reconstructed with fascia lata alone (group C, no stent) survived to 24 weeks (37.5% mortality) and demonstrated slitlike airways on repeated bronchoscopy. Volume measurements demonstrated an average stenosis of 24.8% (range, 14.4%-37.2%). The remaining 6 animals died of airway obstruction. Four of the 16 animals reconstructed with fascia lata and PLLA stent (group C, with stent) survived to 24 weeks (75%

mortality) and demonstrated elliptical airways on bronchoscopy. Twelve of the animals died of airway obstruction. Infolding of the PLLA stents was a frequent observation on bronchoscopy and necropsy in these animals. Volume measurements demonstrated an average stenosis of 14.9% (range, 7.7%-22.7%). With respect to tracheal stenosis in the group C animals, there was a statistically significant difference between the surviving stented and unstented animals using the *t* test ($P = .01$, Figure 2).

The histologic results were quite revealing. In the subcutaneous implants group (group A), 7 (78%) of the

9 complete PGA constructs made with chondrocytes and RGD-modified alginate demonstrated cartilage formation. Of the remaining implants in this group, 1 (11%) demonstrated bone formation and 1 (11%) demonstrated myxoid material. With respect to the PGA constructs made with chondrocytes and unmodified alginate, 7 (78%) of the 9 demonstrated mature cartilage formation. The remaining 2 (22%) implants demonstrated myxoid material. None of the PGA constructs made without chondrocytes demonstrated cartilage formation. Of these implants, 8 (89%) of the 9 showed myxoid material with or without inflammation. One (11%) of the 9 implants demonstrated early bone formation (**Figure 3**).

In the group B animals, the surviving animal reconstructed with the PGA construct and PLLA stent demonstrated cartilage and bone formation at the reconstruction site. Unfortunately, the specimen from the surviving animal reconstructed with the PGA construct alone (group B, no stent) was lost during processing. No histologic analysis was performed on this specimen. Grossly, the engineered tissue had the consistency and flexibility of cartilage.

COMMENT

In-folding of the “finger trap” PLLA stent put the stented group B and C animals at increased risk for mucous plugging. This seemed to be the most likely cause of the increased mortality seen in the stented animals overall. The high mortality seen in the animals reconstructed with the PGA construct alone (group B, no stent) is likely due to inward prolapse or unrestricted growth of the construct. For future studies, the use of an alternative stent material or design may offer rigid support until cartilage forms while avoiding the in-folding that occurs with the PLLA stents we tested.

Further investigation is needed to determine the optimal concentration of alginate, thickness of PGA, and density of chondrocytes. A number of modifications to our protocol may reduce mortality, but would also have an impact on cartilage formation. Using alginate at a higher concentration would perhaps make the construct more rigid, but its effects on cell viability are unknown. Using a smaller thickness of PGA mesh would make the construct less bulky, but also less rigid. Further studies are also needed to learn how to limit the cartilage growth within the desired confines of the PGA mesh. New Zealand White rabbits were used in our study because their tracheas approximate the tracheas of human infants. Work on larger animals would have also likely reduced the mortality rates, but more chondrocytes would have been needed to seed a larger construct, and the applicability of the procedure to a small (eg, infantile) trachea could not be ascertained. We plan to consider modifications to our reconstruction protocol that will lower our mortality rate.

Our present results using fascia lata reconstruction alone had a similar but slightly lower average stenosis than our previously published studies (14.9% vs 23% for the stented animals and 24.8% vs 34% for the unstented animals).¹¹ While continuing to show a benefit to stent-

ing in both cases, this difference may in part be due to a slightly different method of calculating the degree of stenosis. In previous studies, the degree of stenosis was determined by comparing only the most stenotic segment with an adjacent length of normal tracheal lumen. In this study, the degree of stenosis was a measurement of luminal volume loss over a 3-cm tracheal segment compared with an expected (calculated) volume of the same segment had there been no surgical manipulation.

The results of this study support previous studies that indicate cartilaginous tissues can be readily formed by chondrocyte transplantation in PGA scaffolds.^{15,16} The RGD-modified alginate did not appear to improve cartilage formation in this system, in contrast to our previous study.¹⁷ This latter finding may reflect the single, long-term time point examined in the present study, the lower cell density used, or minor differences in alginate reconstitution in this study. In addition, further qualitative and quantitative analysis may be useful in looking at ultrastructural differences in cartilage formation in the RGD-modified PGA constructs compared with the unmodified PGA constructs.

CONCLUSIONS

Animals implanted subcutaneously with PGA constructs containing alginate-encapsulated chondrocytes demonstrated mature cartilage and focal areas of bone formation after 20 weeks. The RGD-modified alginate did not enhance cartilage formation over unmodified alginate, although the quality of the alginate was not analyzed. The mortality was high for animals that underwent tracheal reconstruction with the PGA constructs and for all stented animals. Mature cartilage formation was seen at the tracheal reconstruction site in the surviving animals who underwent implantation at that site—a promising new finding.

Further work is necessary to improve the quality and quantity of cartilage formed and reduce the mortality rate in animals with reconstructed tracheal defects.

Submitted for publication December 30, 2003; final revision received April 28, 2004; accepted May 20, 2004.

Some data from this article were presented as a poster at the American Academy of Otolaryngology–Head and Neck Surgery Meeting; September 20–23, 2003; Orlando, Fla.

Correspondence: J. Fredrik Grimmer, MD, Children’s Hospital Boston, 300 Longwood Ave, Fegan 9, Boston, MA 02115 (johannes.grimmer@tch.harvard.edu).

REFERENCES

1. Grillo HC. Tracheal replacement. *Ann Thorac Surg.* 1990;49:864-865.
2. Jacobs JP, Elliott MJ, Haw MP, Bailey CM, Herberhold C, de Leval MR. Pediatric tracheal homograft reconstruction: a novel approach to complex tracheal stenoses in children. *J Thorac Cardiovasc Surg.* 1996;112:1549-1560.
3. Idriss FS, DeLeon SY, Ilbawi MN, Gerson CR, Tucker GF, Holinger L. Tracheoplasty with pericardial patch for extensive tracheal stenosis in infants and children. *J Thorac Cardiovasc Surg.* 1984;88:527-536.
4. Cosentino CM, Backer CL, Idriss FS, Holinger LD, Gerson CR, Mavroudis C. Pericardial patch tracheoplasty for severe tracheal stenosis in children: intermediate results. *J Pediatr Surg.* 1991;26:879-885.
5. Vacanti CA, Paige KT, Kim WS, Sakata J, Upton J, Vacanti JP. Experimental tra-

- cheal replacement using tissue-engineered cartilage. *J Pediatr Surg.* 1994;29:201-205.
6. Sakata J, Vacanti CA, Schloo B, Healy GB, Langer R, Vacanti JP. Tracheal Composites tissue engineered from chondrocytes, tracheal epithelial cells, and synthetic degradable scaffolding. *Transplant Proc.* 1994;26:3309-3310.
 7. Rowley JA, Madlambayan G, Mooney DJ. Alginate hydrogels as synthetic extracellular matrix materials. *Biomaterials.* 1999;20:45-53.
 8. Humphries MJ. The molecular basis and specificity of integrin-ligand interactions. *J Cell Sci.* 1990;97:585-592.
 9. Menko AS, Boettiger D. Occupation of the extracellular matrix receptor, integrin, is a control point for myogenic differentiation. *Cell.* 1987;51:51-57.
 10. Mooney DJ, Baldwin DF, Suh NP, Vacanti JP, Langer R. Novel approach to fabricate porous sponges of poly(D,L-lactic-co-glycolic acid) without the use of organic solvent. *Biomaterials.* 1996;17:1417-1422.
 11. Robey TC, Valimaa T, Murphy HS, Tormala P, Mooney DJ, Weatherly RA. Use of internal bioabsorbable PLGA "finger-type" stents in a rabbit tracheal reconstruction Model. *Arch Otolaryngol Head Neck Surg.* 2000;126:985-991.
 12. Klagsbrun M. Large-scale preparation of chondrocytes. *Methods Enzymol.* 1979;58:560.
 13. Park DJ, Park SY, Bong JP, Hong KS. Cartilage generation using alginate-encapsulated autogenous chondrocytes in rabbits. *Ann Otol Rhinol Laryngol.* 2000;109:1157-1161.
 14. Alsberg E, Anderson KW, Albeiruti A, Franceschi RT, Mooney DJ. Cell-interactive alginate hydrogels for bone tissue engineering. *J Dent Res.* 2001;80:2025-2029.
 15. Cao YL, Rodriguez A, Vacanti M, Ibarra C, Arevalo C, Vacanti CA. Comparative study of the use of poly(glycolic acid), calcium alginate and pluronics in the engineering of autologous porcine cartilage. *J Biomater Sci Polym Ed.* 1998;9:475-487.
 16. Kojima K, Bonassar LJ, Roy AK, Mizuno H, Cortiella J, Vacanti CA. A composite tissue-engineered trachea using sheep nasal chondrocyte and epithelial cells. *FASEB J.* 2003;17:823-828.
 17. Alsberg E, Anderson KW, Albeiruti A, Rowley JA, Mooney DJ. Engineering growing tissues. *Proc Natl Acad Sci U S A.* 2002;99:12025-12030.